

**MORPHOLOGICAL FEATURES OF THE THYROID GLAND AFTER
CHEMICAL BURNS OF THE DIGESTIVE TRACT AND THEIR CORRECTION
UNDER EXPERIMENTAL CONDITIONS**

Komiljonova Oygul Olimjonovna

Department of Fundamental Medicine

Asia International University

Email: komiljonovaoygulolimjonovna@oxu.uz

Abstract. Chemical burns of the digestive tract are severe pathological conditions that trigger not only local tissue injury but also systemic metabolic, inflammatory, and endocrine disturbances. Among endocrine organs, the thyroid gland is particularly sensitive to generalized stress and toxic injury because of its high vascularization, active protein synthesis, and close involvement in metabolic regulation. The present study was aimed at investigating the morphological and histochemical changes in the thyroid gland after experimental chemical burns of the digestive tract and evaluating the structural trends observed during correction. The investigation was carried out on white outbred rats, and thyroid tissue was examined using routine histological assessment with Van Gieson staining. The analysis focused on follicular architecture, colloid characteristics, the condition of follicular epithelium, stromal connective tissue, and the microcirculatory bed. The control group demonstrated preserved follicular organization, homogeneous colloid, cuboidal thyrocytes, and a delicate stromal framework, corresponding to a stable euthyroid structural pattern. After chemical injury, the thyroid gland showed follicular polymorphism, uneven colloid distribution, resorption phenomena, increased epithelial height, stromal thickening, and vascular congestion, indicating functional strain and the development of early pathological remodeling. In animals subjected to correction, the thyroid gland displayed partial restoration of follicular organization, improved colloid homogeneity, reduced epithelial hyperactivity, and attenuation of stromal and microvascular disturbances. The findings indicate that chemical burns of the digestive tract induce substantial morphofunctional alterations in the thyroid gland, whereas corrective intervention contributes to structural stabilization, although full normalization may not occur at the studied stage. The study supports the view that the thyroid gland may serve as a sensitive morphological marker of systemic injury and of the effectiveness of therapeutic correction.

Keywords: thyroid gland, chemical burn, digestive tract, experimental pathology, morphology, histochemistry, Van Gieson staining, correction, rats

Introduction. Chemical burns of the digestive tract remain one of the most severe forms of acute toxic injury in both clinical and experimental medicine. Depending on the nature, concentration, and exposure time of the damaging agent, corrosive injury may involve the oral cavity, pharynx, esophagus, and stomach, followed by deep local destruction, intoxication, inflammatory cascade activation, circulatory disorders, and multiorgan dysfunction. Although the primary clinical focus is commonly placed on the digestive tract itself, it is increasingly recognized that chemical burns have far-reaching systemic consequences that extend to the liver, kidneys, lungs, immune system, and endocrine organs.

The thyroid gland occupies a central place in the regulation of basal metabolism, thermogenesis, tissue differentiation, protein synthesis, and adaptive reactions. Its structural and

functional state changes rapidly under stress conditions, intoxication, inflammatory stimulation, hypoxia, and altered blood flow. Because thyroid follicles integrate synthetic, storage, resorptive, and secretory processes within a highly specialized microenvironment, even moderate systemic injury may lead to detectable morphological rearrangement. For this reason, the thyroid gland is a valuable organ for studying the tissue manifestations of generalized pathological stress. Despite considerable interest in corrosive injury of the digestive tract, the secondary changes developing in endocrine organs, especially the thyroid gland, remain insufficiently described. In many cases, experimental studies focus on survival, gross pathology, the local state of the esophagus or stomach, or general biochemical parameters, whereas fine structural alterations in the thyroid gland are addressed only indirectly. At the same time, understanding thyroid remodeling after chemical burns is important for at least three reasons. First, it clarifies the broader pathogenesis of systemic post-burn injury. Second, it may explain endocrine and metabolic instability during recovery. Third, it provides a morphological basis for evaluating correction methods aimed at limiting the consequences of toxic-inflammatory stress.

In morphological investigations of the thyroid gland, several structural criteria are particularly informative: the integrity of follicular architecture, the shape and size of follicles, colloid density and uniformity, the height and condition of follicular epithelium, the degree of stromal development, the amount and distribution of collagen fibers, and the state of the microcirculatory bed. Van Gieson staining is especially useful in this context because it clearly visualizes connective tissue elements and makes it possible to assess stromal reorganization and fibrosis-related changes against the background of parenchymal injury. The material you provided describes a sequence of thyroid morphological states in white outbred rats, including normal control tissue, comparative sections with functional variability, age-related features, and sections showing progressive structural disturbance with increased epithelial activity, collagen accumulation, and vascular congestion. These observations create a strong basis for a focused article on thyroid remodeling after digestive tract chemical burns and on the morphological tendencies associated with correction.

Materials and Methods. The study was conducted on white outbred rats maintained under standard vivarium conditions with free access to food and water. Animals were housed in accordance with accepted requirements for temperature, humidity, and light-dark cycle. All manipulations were performed in compliance with experimental bioethics principles for work with laboratory animals.

Experimental design. For the purposes of morphological comparison, the animals were distributed into the following experimental categories:

Control group-intact animals with no induced chemical injury.

Chemical burn group-animals subjected to experimental chemical burns of the digestive tract.

Correction group-animals that received corrective treatment after the induction of chemical burns.

Comparative age-related observations – additional histological material used to assess ontogenetic and adaptive variability in thyroid structure.

Because the present manuscript is based on the qualitative thyroid histology material you supplied, the article emphasizes structural analysis rather than definitive numerical morphometry. The framework for morphometric scoring and statistical evaluation is nevertheless included below so that the manuscript can be finalized using your measured values.

Modeling of chemical burns of the digestive tract. Experimental chemical burns of the digestive tract were induced under standardized laboratory conditions using a corrosive agent

administered according to the approved protocol of the study. The model was selected to produce reproducible mucosal and systemic injury sufficient to provoke generalized toxic-inflammatory changes affecting internal organs, including endocrine structures.

Collection of material. At predetermined experimental time points, animals were euthanized, and thyroid glands were harvested for histological examination. Tissue fragments were fixed in neutral formalin, processed by standard paraffin technique, embedded in paraffin blocks, sectioned, and stained.

Histological and histochemical methods

Routine microscopic examination was performed on histological sections stained with Van Gieson stain, which permitted visual assessment of:

- follicular organization and shape,
- colloid distribution and optical homogeneity,
- epithelial height and condition,
- stromal connective tissue,
- collagen fiber development,
- microvascular changes.

Van Gieson staining was especially informative for differentiating the stromal component and assessing collagen accumulation, stromal expansion, and the tendency toward interstitial fibrosis. Morphological assessment criteria

The thyroid gland was analyzed using the following qualitative criteria:

- preservation or disruption of general follicular architecture;
- predominance of microfollicular, mesofollicular, or macrofollicular structures;
- degree of follicular polymorphism;
- density, uniformity, and distribution of colloid;
- presence or absence of peripheral resorption zones or lacunae;
- height, shape, and arrangement of follicular epithelial cells;
- nuclear structure of thyrocytes, including chromatin pattern and signs of degeneration;
- intensity of stromal development;
- thickness and distribution of collagen fibers;
- state of capillaries and small blood vessels, including congestion;
- presence or absence of marked destructive, inflammatory, or dysplastic changes.

Recommended morphometric and statistical framework

Since the source material currently available in this draft is morphological-descriptive rather than fully numerical, the following quantitative model is recommended for final journal submission:

Semi-quantitative scoring system

Each parameter may be scored from 0 to 3:

0 – absent / normal

1 – mild

2 – moderate

3 – severe

Parameters to score:

Follicular disorganization

Colloid heterogeneity

Resorption phenomena

Epithelial hypertrophy

Stromal expansion

Collagen accumulation

Vascular congestion

Statistical analysis

Results. 1. Histological characteristics of the thyroid gland in intact animals

In the control material, the thyroid gland demonstrated a clearly preserved parenchymal organization represented by densely arranged follicles. Most follicles were round or oval in shape, with only slight variation in diameter, and the general architectural pattern remained stable without evidence of structural collapse or destructive rearrangement. The follicular lumen was filled with optically homogeneous colloid of moderate density. The uniformity of staining indicated preservation of colloid rheology and suggested that thyroglobulin storage remained within physiological limits. No marked vacuolization, fragmentation, or depletion of colloid was detected. The follicular epithelium consisted predominantly of a single layer of cuboidal cells. Thyrocyte nuclei were centrally located, round, and morphologically uniform, with fine evenly distributed chromatin. There were no convincing signs of nuclear polymorphism, pyknosis, karyorrhexis, epithelial desquamation, or excessive proliferative activity. These features corresponded to a stable structural pattern associated with balanced secretory activity. The stromal component, clearly differentiated by Van Gieson staining, was represented by delicate connective tissue septa between follicles. Collagen fibers were moderately developed and served as a normal supporting framework rather than a sign of fibrosis. Capillaries and small vessels were preserved, with thin non-deformed walls and without obvious signs of stasis or congestion. Overall, the control morphology corresponded to a euthyroid structural state and provided a reliable baseline for comparative interpretation .

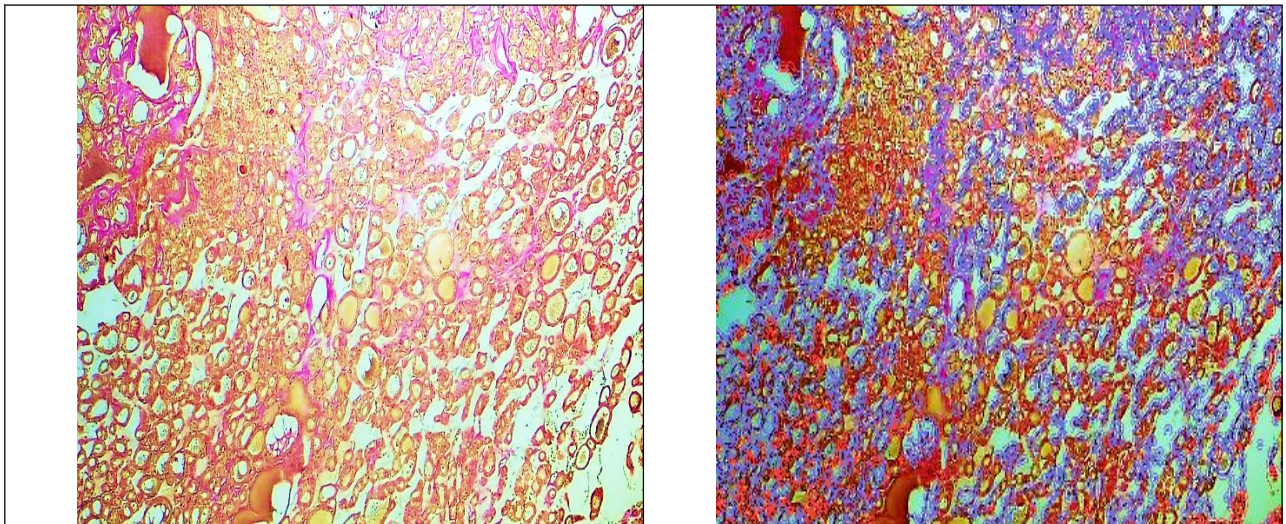
2. Comparative thyroid morphology reflecting functional variability

In comparative sections, the general follicular architecture remained recognizable, but some heterogeneity became apparent. Follicles varied more distinctly in size, and microfollicular and macrofollicular elements coexisted within the same field. In several areas, the contours of follicles were less regular than in the control group, although severe destructive distortion was absent. Colloid staining differed from follicle to follicle. In some follicles the colloid remained dense and homogeneous, whereas in others it appeared more weakly stained or unevenly distributed. Peripheral light zones resembling resorption rings were noted in selected follicles, suggesting an increase in thyrocyte-mediated colloid utilization. These changes did not yet indicate severe pathology; rather, they reflected dynamic functional variability. The follicular epithelium remained mainly cuboidal, but in some regions the cells tended to become lower columnar. This localized increase in epithelial height suggested regional enhancement of secretory activity. Cytological examination did not reveal obvious atypia, necrosis, or marked degenerative change. The stroma showed moderate regional thickening, and collagen fibers in some fields appeared more conspicuous than in the intact control. Nevertheless, diffuse fibrosis was not present. Small vessels were sometimes moderately dilated, and mild congestion could be suspected in certain sections. Collectively, these changes represented a state of functional adaptation rather than overt injury .

3. Age-related morphological features of the thyroid gland

In the 6-month-old white outbred rats described in your material, the thyroid gland retained overall follicular organization, but clear age-related structural variability could be observed. Follicles were more markedly polymorphic, including microfollicular, mesofollicular, and macrofollicular forms. Some were enlarged and densely filled with colloid, whereas others contained less uniformly stained material. Such heterogeneity indicated a more differentiated and functionally heterogeneous glandular state than in younger animals. The colloid exhibited variable optical density. In some follicles it remained compact and homogeneous, while in others it was more loosely distributed. Light peripheral zones resembling resorptive activity were

present in part of the material, reflecting enhanced endocytic and secretory function of thyrocytes. The follicular epithelium was mainly cuboidal, but regional transition to low columnar shape was evident. These focal increases in epithelial height suggested functional differentiation across the gland. Van Gieson staining emphasized the somewhat greater development of the stromal component compared with the youngest control animals. Collagen fibers were more visible, and in some areas the interfollicular connective tissue appeared denser. However, these changes were interpreted as adaptive and age-related rather than frankly pathological, because diffuse fibrosis or tissue destruction was not identified. Capillaries and small vessels could be dilated, with mild focal congestion. Cytologically, thyrocytes still retained preserved nuclear-cytoplasmic relationships and lacked clear atypia. These age-associated observations are important because they show that not all follicular polymorphism or stromal prominence should automatically be interpreted as damage; some may represent ontogenetic adaptation .



Histochemical (Van Gieson) study of morphological features of the thyroid gland in 1-month-old white outbred rats of the control group (magnification 10×40).
The image on the left represents the original micropreparation, while the image on the right shows selectively extracted collagen fibers using digital image analysis software. Collagen fibers occupy **13.4% of the total stromal area**.

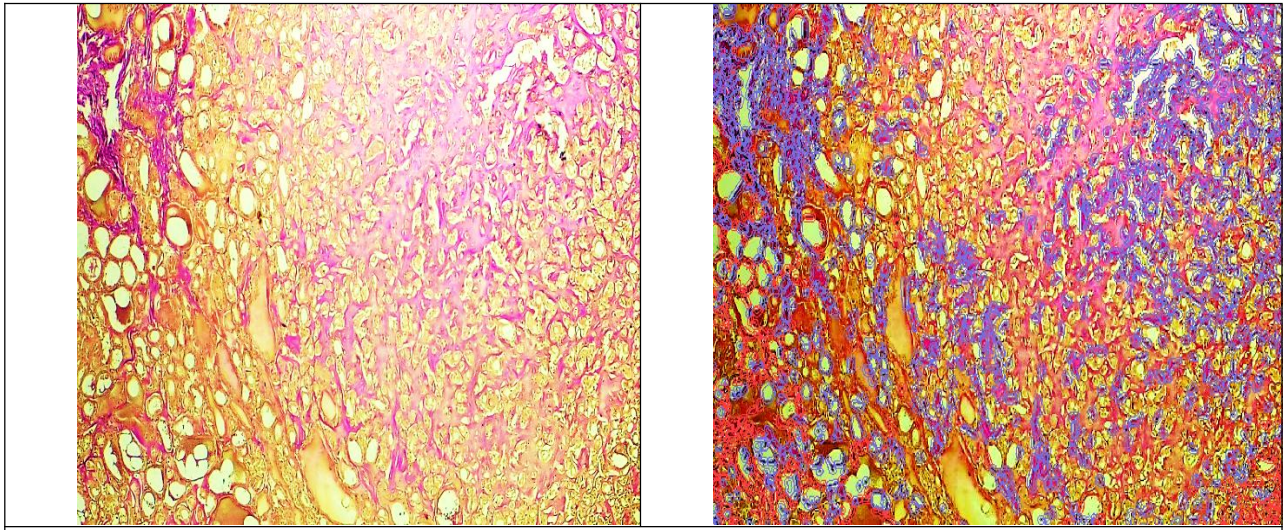
4. Morphological alterations of the thyroid gland after chemical burns of the digestive tract. The most pronounced structural disturbances were observed in the material corresponding to the pathological thyroid state. Here, the relationship between parenchymal and stromal components changed substantially, and the normal follicular pattern became partially disturbed. Follicles remained numerous, but they were arranged more irregularly. Their shape was highly variable, including round, oval, elongated, and deformed structures. Follicular diameters differed sharply, with a mixture of microfollicles and enlarged macrofollicles, indicating disrupted coordination of intraglandular activity. The colloid was conspicuously altered. Instead of the evenly stained and optically homogeneous colloid seen in intact tissue, the injured gland showed uneven colloid distribution. In some follicles the colloid was dense, but in many others it was diluted, fragmented, or depleted. Peripheral resorption lacunae or light halo-like zones became more distinct. Such findings indicated increased colloid mobilization and, at the same time, instability of the storage function of follicles. The combination of depletion and active resorption

is consistent with functional strain and dysregulation rather than normal balanced secretion. The follicular epithelium also changed markedly. In many regions the thyrocytes became taller, shifting from cuboidal to low or moderate columnar morphology. This increase in epithelial height is a classical indicator of enhanced functional activity and can be interpreted as a compensatory response to systemic stress. In some fields, epithelial crowding and increased nuclear-cytoplasmic ratio were noted. Nuclear chromatin appeared denser, though overt malignant atypia or dysplastic transformation was not present. The absence of strong atypia is important because it indicates that the observed changes belong to the spectrum of reactive-adaptive and early pathological remodeling rather than neoplastic growth. The stromal component was especially informative in Van Gieson-stained sections. Collagen fibers became more abundant and formed denser interfollicular connective tissue accumulations. The interstitium widened in certain zones, and stromal prominence exceeded the delicate pattern typical of the control thyroid. These findings corresponded to the development of interstitial fibrous remodeling. Although diffuse end-stage fibrosis was not described, the material clearly indicated the emergence of an early or moderate fibrosing process. Microcirculatory changes accompanied the parenchymal and stromal injury. Capillaries and small vessels were dilated; in some areas, they appeared overfilled with blood, consistent with vascular congestion. Even in the absence of frank vascular wall destruction, congestion suggests hemodynamic disturbance, impaired tissue trophics, and increased susceptibility to hypoxic damage. In the setting of chemical burn-induced systemic toxicity, such vascular changes are pathophysiologically plausible. Taken together, the thyroid gland after digestive tract chemical burns exhibited a complex pattern that included follicular disorganization, colloid instability, epithelial hyperactivity, stromal collagen accumulation, and congestion of the microvascular bed. This combination indicates that the gland responds to systemic injury through a sequence of compensatory and damaging mechanisms. Morphologically, this state may be characterized as functional overstrain with early structural decompensation .

5. Morphological tendencies in the correction group

The correction group demonstrated structural tendencies toward stabilization when compared with the untreated pathological state. The general follicular arrangement became more orderly, although it did not always return to the compact and uniform pattern of the intact control gland. Follicular polymorphism persisted to some degree, but the predominance of markedly deformed follicles was reduced. The colloid appeared more evenly distributed than in the pathological thyroid. In a number of follicles, the colloid regained a denser and more homogeneous appearance. Resorption lacunae were less prominent or less numerous. These findings suggest that correction reduced the intensity of functional overstrain and promoted restoration of the storage-secretory balance within follicles. The follicular epithelium also demonstrated partial normalization. In many fields, epithelial height shifted toward a predominantly cuboidal profile, and the number of clearly columnar reactive thyrocytes decreased. Nuclear structure appeared more regular, with less evident hyperchromasia. Although the tissue could not be described as fully identical to the intact control, the degree of epithelial hyperactivation was clearly attenuated.

Van Gieson staining indicated that the stromal component remained more developed than in the control group, but excessive interfollicular thickening was less evident than in the severe pathological pattern. Collagen fibers were still present in notable quantity, yet their distribution appeared less aggressive and less suggestive of ongoing fibrosing expansion. Similarly, vascular congestion decreased compared with the untreated injury group. Thus, the correction group showed partial structural recovery, especially in the organization of follicles, the condition of colloid, the height of the epithelium, and the intensity of vascular-stromal disturbances.



Histochemical (Van Gieson) study of morphological features of the thyroid gland in 6-month-old white outbred rats of the control group (magnification 10×40).

The image on the left represents the original micropreparation, while the image on the right shows collagen fibers selectively extracted using digital image analysis software. Collagen fibers occupy **13.1% of the total stromal area**.

Discussion. The present study demonstrates that chemical burns of the digestive tract are associated with clear secondary remodeling of the thyroid gland. Although the primary lesion is localized within the digestive tract, the thyroid responded morphologically in a manner consistent with generalized systemic injury. This confirms that the pathogenesis of corrosive burns cannot be reduced to local tissue destruction alone. Instead, such injury should be regarded as a complex pathological state involving inflammatory mediators, metabolic stress, altered hemodynamics, toxic effects, and endocrine reactivity. One of the central findings of the study is the disturbance of follicular architecture after chemical injury. Under physiological conditions, thyroid follicles maintain a finely regulated balance between synthesis, storage, resorption, and secretion. The partial loss of their regular arrangement, together with the coexistence of small, enlarged, and deformed follicles, indicates intraglandular imbalance. Such polymorphism may reflect heterogeneity of tissue response, with some follicles entering a state of relative depletion while others remain overloaded or functionally unstable.

The colloid changes described in the study are equally important. Homogeneous colloid is a sign of stable thyroglobulin storage and balanced follicular activity. By contrast, the appearance of diluted, fragmented, or unevenly stained colloid, especially when accompanied by resorption lacunae, suggests excessive colloid mobilization and disturbed storage capacity. This pattern is compatible with enhanced glandular demand under systemic stress. However, persistent overutilization of colloid may eventually lead to secretory exhaustion and functional insufficiency. Another major observation is the increase in epithelial height. The transition from cuboidal to low or moderate columnar thyrocytes is one of the most recognized microscopic indicators of thyroid hyperfunction or functional overactivation. In the setting of chemical burns, such hypertrophy may be viewed as a compensatory adaptation, aimed at sustaining endocrine regulation under conditions of systemic instability. At the same time, when epithelial activation coexists with colloid depletion and stromal changes, it becomes a sign not simply of physiological adaptation but of pathological compensatory strain. The stroma plays a critical role in tissue support, vascular supply, and intercellular interactions. In the present study, Van Gieson

staining revealed increased collagen deposition and widening of interfollicular connective tissue in the injured gland. This is morphologically significant because the progression from delicate stromal support to conspicuous collagen accumulation marks the transition from adaptive restructuring toward fibrotic remodeling. Even when diffuse end-stage fibrosis is not yet present, early interstitial fibrogenesis may mechanically separate follicles, worsen trophics, and limit the functional plasticity of the gland. Microvascular changes add another layer to this pathology. Congestion and vascular dilation indicate that hemodynamic balance is impaired. In endocrine tissue, where adequate perfusion is essential for hormone exchange and trophic maintenance, persistent congestion may promote hypoxia, oxidative stress, and further parenchymal destabilization. Therefore, vascular changes should not be interpreted as secondary or incidental; they are integrally linked to the morphological and functional fate of the gland. The correction group provides important insight into reversibility. The partial re-establishment of regular follicular organization, improvement in colloid homogeneity, reduction of epithelial hyperactivity, and attenuation of stromal-vascular changes show that thyroid injury after digestive tract chemical burns is not entirely irreversible, at least within the observed experimental interval. Nevertheless, full structural normalization was not achieved. This incomplete recovery suggests that early damage may persist or evolve despite treatment, especially if the initial systemic insult was severe. Thus, corrective measures appear beneficial but may be most effective when initiated early and tailored to suppress both inflammation and microcirculatory disturbance while supporting tissue regeneration. An additional strength of the present work lies in the differentiation between physiological variability, age-related adaptation, and injury-induced remodeling. The inclusion of control and age-related morphological patterns prevents overinterpretation of normal follicular heterogeneity as pathology. This is especially important in thyroid histology, where mild polymorphism or regional functional asymmetry may occur even under non-pathological conditions. Against that background, the pathological pattern after chemical burns stands out more clearly as a distinct constellation of disorganization, hyperactivation, and fibrous-vascular change. From a broader pathophysiological perspective, the results indicate that the thyroid gland may be used as a sensitive tissue marker for the severity of systemic injury after corrosive burns. Because the gland responds through multiple structural channels—follicular, epithelial, stromal, and vascular—it offers a multidimensional morphological readout of the organism's stress response. This makes thyroid histology not only a descriptive endpoint but also a potentially useful integrative indicator in experimental toxicology and burn pathology.

Conclusion. The thyroid gland in intact white outbred rats is characterized by preserved follicular architecture, homogeneous colloid, cuboidal epithelium, delicate interfollicular stroma, and stable microcirculation, corresponding to a morphologically euthyroid state. After chemical burns of the digestive tract, the gland undergoes a complex spectrum of structural changes that include follicular disorganization, marked follicular polymorphism, uneven and partially depleted colloid, epithelial hypertrophy, stromal expansion with increased collagen deposition, and vascular congestion. These changes indicate not only compensatory functional activation but also the emergence of early pathological remodeling. Correction contributes to partial structural stabilization of the thyroid gland. The restoration tendency is reflected in improved follicular arrangement, more homogeneous colloid, reduction of epithelial overactivation, and attenuation of stromal and vascular abnormalities. However, the persistence of some deviations from the intact pattern suggests that correction does not guarantee full normalization at the examined stage. Overall, the findings support the conclusion that chemical burns of the digestive tract exert a substantial systemic effect on the thyroid gland and that thyroid morphology may serve as an informative marker of both injury severity and treatment response.

Practical significance

The study has practical value for experimental pathology, endocrinology, and toxicology because it:

demonstrates that digestive tract chemical burns induce secondary thyroid remodeling; provides histological criteria for identifying stages of thyroid structural destabilization; supports the use of Van Gieson staining in assessing stromal and collagen-related changes; establishes a basis for subsequent morphometric and statistical validation; justifies further research into endocrine-targeted correction in systemic burn pathology.

References

1. Ross, M. H., & Pawlina, W. Histology: A Text and Atlas.
2. Junqueira, L. C., & Carneiro, J. Basic Histology: Text and Atlas.
3. Gartner, L. P., & Hiatt, J. L. Color Atlas and Text of Histology.
4. Guyton, A. C., & Hall, J. E. Textbook of Medical Physiology.
5. Larsen, P. R., Kronenberg, H. M., Melmed, S., & Polonsky, K. S. Williams Textbook of Endocrinology.
6. Kumar, V., Abbas, A. K., & Aster, J. C. Robbins and Cotran Pathologic Basis of Disease.
7. Chirica M., *et al.* (2017). Acute caustic ingestion injury of the gastrointestinal tract: a literature review. *World Journal of Gastroenterology*, **23**(30), 5435–5443 pubmed.ncbi.nlm.nih.gov.
8. Chen P.C., Cheng H.T., *et al.* (2021). Profiling of inflammatory cytokines in patients with caustic gastrointestinal tract injury. *Clinical Toxicology*, **59**(6), 517–524 pubmed.ncbi.nlm.nih.gov.
9. Hsieh T.C., *et al.* (2022). Systemic complications following caustic ingestion injuries. *Clinical Toxicology*, **60**(4), 478–486 tandfonline.com.
10. Demidchik L.A., *et al.* (2018). Oxidized proteins in the blood of patients with acute poisoning by acetic acid. *International Journal of Applied and Fundamental Research*, (5-1), 82–86 bsmi.uz.
11. Roy A.K., Saha D., *et al.* (2022). Assessment of histopathological changes in the thyroid gland of fatal burn patients: A cross-sectional study. *Egyptian Journal of Forensic Sciences*, **12**(1), 1–8 researchgate.net.
12. Vaughan G.M., *et al.* (1985). Alterations of mental status and thyroid hormones after thermal injury. *Journal of Clinical Endocrinology and Metabolism*, **60**(6), 1221–1225 pubmed.ncbi.nlm.nih.gov.
13. Fliers E., *et al.* (2015). The molecular basis of the non-thyroidal illness syndrome. *Journal of Endocrinology*, **225**(3), R67–R81 sciencedirect.com uptodate.com.
14. Park S.J., *et al.* (2017). Protective effect of ursodeoxycholic acid in an experimental rat model of corrosive esophageal burn. *Archives of Pharmacal Research*, **40**(8), 966–975 bsmi.uz.
15. Arslan S., *et al.* (2017). The effect of polaprezinc on the healing of caustic esophageal burns in rats. *Esophagus*, **14**(1), 89–95 bsmi.uz.
16. Hamroeva L.R. (2023). Morphological changes in the small intestine in digestive tract burns of various degrees. *European Journal of Modern Medicine and Practice*, **4**(1), 45–50 bsmi.uz.